



Assessment of the Anti-apoptotic Effects of *Peganum harmala* Leaf Extract on Type 2 Diabetes in the Kidney of Male Wistar Rats

Forough Kajbaf¹ , Shahrbanoo Oryan², Ramesh Ahmadi^{3*} , Akram Eidi¹

¹Department of Biology, Science and Research Branch, Islamic Azad University, Tehran, Iran

²Department of Animal Sciences, Faculty of Biological Sciences, Kharazmi University, Tehran, Iran

³Department of Animal Sciences, Faculty of Basic Sciences, Islamic Azad University of Qom, Qom, Iran

***Corresponding author:**

Ramesh Ahmadi,
Islamic Azad University, Qom
Branch, 15 Khordad Blv,
Qom, Iran;
P.O.Box: 37185364,
Tel: +982537780001,
+989122024619,
Email: Ramahmd@yahoo.com

Abstract

Background: Growing evidence has shown that the apoptosis of cells plays an important role in the advancement of the Diabetic nephropathy (DN).

Objectives: This study attempted to discover the therapeutic potential of *Peganum harmala* leaf extract in the apoptosis of diabetic kidney disease.

Methods: In the present experimental research, 32 male Wistar rats were studied, and diabetes was induced by streptozotocin (STZ) (65 mg/kg). The animals were randomly divided into four groups (n=8, in each group) as follows: control, diabetic, control+leaf extract, diabetic+leaf extract. For our purposes, the methanolic extract of *P. harmala* leaves (150 mg/kg) was given by gavage for 28 days. Flow cytometry and real-time polymerase chain reaction (PCR) analyses were utilized to determine the percentages of apoptotic cells. Also, histological alterations and blood biochemical parameters were evaluated.

Results: The *P. harmala* leaf extract has a high amount of flavonoids (25.84%), a lower percentage of alkaloids (0.14%), and some antioxidant properties. Serum urea ($P<0.001$) and apoptosis ($P<0.05$) significantly elevated in diabetic rats relative to the control ones. The mean of fasting blood creatinine, urea, and albumin level was not significantly changed in diabetic+leaf extract rats as compared to the diabetic ones. Histopathological results also displayed that diabetic complications in the kidney could not be improved following treatment by the leaf extract of *P. harmala*. In addition, the leaf extract could not significantly reduce the apoptosis and caspase-3 expression compared to diabetics in renal cells.

Conclusion: Based on our findings, the leaf extract of *P. harmala* is unable to inhibit apoptosis in the diabetic kidney model.

Keywords: Apoptosis, *Peganum harmala*, Diabetes, Kidney, Caspase-3

Received: 27 October 2020
Accepted: 16 November 2020
ePublished: 30 December 2020



Background

The most costly and prevalent chronic disease expected up to 2025 is diabetes, particularly diabetes mellitus, accounting for 439 million individuals per year (1). Diabetic nephropathy (DN) is recognized as a long-lasting problem of diabetes and arises from the extension of the glomerular mesangium and the extreme growth of extracellular matrix proteins (2). One of the common complications occurred in most disease conditions is apoptosis expansion in the affected organs or tissues (3).

In insulin-resistant metabolic disorders, apoptosis often leads to imbalance in the cellular signaling rate and unusual cell efficiency by supporting pro-apoptotic ways and lesions progress (4). Immediately after reaching out the cytosol, apoptotic signaling molecules can use caspase-9. Instantaneously via cleavage, the downstream effector caspase-3 is activated by this enzyme and accordingly can induce apoptosis irreversibly[4]. The condition of

hyperglycemia advances apoptosis in diverse variety of cells in DN (5). Evidence has proven that the high concentration of glucose promotes apoptosis in renal proximal tubular epithelial cells (6). Therefore, identifying the agents that influence apoptotic factors and the apoptotic processes can clarify the unknown aspects of disease progression and provide new therapies (7).

Treatment with plant-based drugs has recently received a special attraction. *Peganum harmala* is a herb belonging to the Zygophyllaceae family and found in North Africa and East Mediterranean regions (8). This wild plant is famous for its antidepressant, hallucinogenic, antitumor, hypothermic, antifungal, antibacterial, anti-dermatosis, antioxidant, anti-inflammatory, antimutagenic (9), and analgesic attributes (10). One of the main products of this plant is the seed that are applied in traditional medicine for controlling glucose in cases with diabetes (11). Harmine and harmalol extracted from *P. harmala*

leaves are the most representative β -carboline alkaloids (12). Other components released from *P. harmala* include deoxyvasicinone, L-vasicinone, vasicine, evodiamine, and fagomine (13). Harmine is an active element of *P. harmala* and known to have pharmacologic properties, mainly as an antioxidant (14). It has also been suggested that *P. harmala* possesses cytoprotective effect (15).

Streptozotocin (STZ) is typically used to induce diabetes in animals such as rats and mice, owing to its toxic effects that cause oxidative impairment, as well as hepatic and renal injuries (16). Apoptosis happens in interstitial and tubular cells of the kidney in diabetes induced by STZ (17). Researchers have found that the levels of urea, uric acid, and creatinine significantly increase in diabetic rats induced by STZ (18). Hence, in this study, we used STZ to induce an animal diabetic model.

Findings of a study have revealed that antioxidant plant-derived compounds could diminish complications due to oxidative stress and apoptosis and could enhance antioxidant enzymes activity (19). It has also been affirmed that treatment by flavone (20) and flavonoid (21) mitigates the renal dysfunction, oxidative stress, and fibrosis in diabetic rats, and inhibits inflammation and apoptosis in the kidney tissue. Former observations have confirmed the beneficial properties of nitrogenous compounds, such as alkaloids, on preventing the apoptosis of different organs (22,23).

Studies on the chemical compositions of *P. harmala* have suggested that the leaves of this plant are comprised of various components, particularly alkaloids and flavonoids (14,15,24). It has also been explored that *P. harmala* leaf extracts benefit from antioxidant (25), antibacterial (26,27), and cytotoxic (28) activities due to polyphenol compositions. Considering the effective role of alkaloids and flavonoids in the inhibition of apoptosis (19-23) and very scant investigations of the anti-apoptotic properties of *P. harmala*, the current research was undertaken to evaluate the anti-apoptotic effect of the leaf extract of *P. harmala*, based on its alkaloids and flavonoids, in type 2 diabetic model rats.

Methods and Materials

Chemicals and Instruments

STZ and QIAzol lysis reagent were obtained from Sigma-Aldrich (USA) and Qiagen (Germany), respectively. Harmine ($C_{13}H_{12}N_2O$) was purchased from Sigma-Aldrich (USA), Trypsin from Merck (Germany), DNase from Qiagen (Germany), CYBER Green from ABI (USA), and Oligo diet from MWG/Biotech (Germany).

Creatinine, albumin, and urea kits were procured from Pars Azmoon (Iran) and APC Annexin V Apoptosis Detection Kit with propidium iodide (PI) from BioLegend (USA).

Plant Material

In the late spring, *P. harmala* was gathered from a place near Zahedan city in Sistan and Baluchestan province of Iran and approved by the Central Herbarium of Iran (TARI; number: 107208). After the plant was dried at ambient temperature, separation of the leaf was carried out. After placing the chopped plant in a soxhlet extractor (the middle section), 500 mL of a solvent (methanol 80%) was added to a balloon. It took 3-4 hours to extract the sample, which was then analyzed by a chromatographer and a wavelength UV detector (both from KNAUER, Germany) at 330 nm. The high-pressure liquid chromatography (HPLC) analysis was accomplished with the analytical column (C18) and also with the mobile phase (isopropyl alcohol:acetonitrile:water:formic acid [100:100:300:3]), at the flow rate of 1 mL.

Animals and Experimental Design

A total of 32 male rats (250-300 g) were selected for this experimental study. The animals were preserved in laboratory conditions with a 12-hour-light/dark cycle and access to water and standard food. All the animals were randomly allotted to four groups of eight rats each, including control, diabetic, control recipient leaf extract (C+L), and diabetic recipient leaf extract (D+L).

Induction of Type 2 Diabetes

Following the dilution of 65 mg/kg of STZ with 3 mL Milli-Q water, all the animals were fasted for 12 hours before the diabetes induction. Subsequently, the intraperitoneal injections of STZ were performed, and the selective doses were determined with regard to the animal's body weight. The fasting blood glucose concentration was determined daily for 10 days. After this period, the animals with a blood glucose level more than 200 mg/dL were considered as diabetic. The leaf extract (150 mg/kg) was given by gavage to the rats for 28 days, and then the animals were anesthetized *intraperitoneally* with 10% ketamine (50 mg/kg) and 2% xylazine (10 mg/kg). Subsequently, kidneys were removed, and blood samples were collected. In the end, fasting blood creatinine, urea, and albumin were measured using the diagnostic kit of Pars Azmoon Company (Tehran, Iran), with the aid of an Autoanalyzer (Alpha-Classic AT Plus, Tajhizat Sanjesh, Iran).

Hematoxylin and Eosin (H&E) Staining

After fixing in 4% paraformaldehyde for at least 24 hours, the kidney tissues were sliced (3-5 μ m). Tissue slides were first moderately over-stained with hematoxylin for 3-5 minutes, and then incubated in acidic alcohol for a few seconds until the slides looked red. Afterwards, they were washed with tap water to eliminate the acid. Bicarbonate was also used for 2 minutes till the nuclei were blue-stained. After rinsing in tap water for 3 minutes and exposing

to eosin for 2 minutes, the hematoxylin-stained slides were placed in 70% ethanol, followed by three washings with 95% ethanol for 5 minutes. Finally, the slides were transferred to absolute ethanol for clearance. Using a light microscope (Olympus Microscope CX21, China), the stained images were captured.

Argyrophil Nucleolar Organizer Region Staining

By using the PLOTON method, the sections of the kidney tissue were stained with argyrophil nucleolar organizer region (AgNOR). For each case, the solid sections (3 μm) of formalin fixed paraffin-embedded blocks samples processed routinely were dewaxed and dehydrated in xylene and with alcohols, respectively. The incubation of tissue sections was carried out in darkness at 37°C (room temperature) for a time period of 38 minutes and with a fresh solution in which two parts of 2% gelatin, 1% formic acid, and one part of the 50% aqueous silver nitrate solution were mixed. After placing in a 1% solution of gold chloride for a period of 5 minutes, rinsing in running deionized water, dehydrating in ascending alcohol concentrations, the slides were cleared in xylene and mounted with distyrene plasticizer xylene (DPX). Using a light microscope (Olympus Microscope CX21, China), the AgNORs were observed as brown to black intranuclear dots with diverse masses.

Single-Cell Preparation

The single-cell stage of kidney tissue was performed at the following four stages: stage one, trypsin (0.25 g) was dissolved in physiological serum (100 mL); stage two, the DNase solution was prepared; stage three, DNase solution (50 μL) was added to trypsin (5 mL); stage four, the kidney tissue was rinsed with phosphate buffered saline (PBS) to remove the remaining blood. The tissue was subsequently crushed. In the next step, 0.25% trypsin (100 μL) and 0.5% DNase mixture was added to a microtube containing the desired amount of crushed tissue, which was steadily pipetting up and down (every 10 minutes, at 37°C for 5 minutes) until fully mixed; this process took 30 minutes. To inactivate the enzyme, bovine serum (5 μL) was added to the microtube, and then its content was centrifuged at 1500 rpm at 44°C for 5 minutes. The supernatant was thrown out, and the remainder was added to a new microtube. After the microtube was mixed with the PBS, the tube was maintained at -80°C. Ten minutes before flow cytometry examinations, a mixture of buffer, propidium iodide (PI), and annexin (100, 10, and 5 μL , respectively) was added to the microtube, and apoptosis was assessed.

Apoptotic Experiments

After transferring to the binding buffer solution (1 mL), single cells (100 μL , 10^5 cells) were added to a cytometric tube. Following the addition of annexin-FITC (5 μL) to the tube and its incubation in darkness at room temperature

for 15 minutes, binding buffer (1 mL) was transferred to the tube, which was then centrifuged at 1500 rpm at 37°C for 15 minutes. Next, the supernatant was discarded, and 100- μL of binding buffer was added to the remaining. Then 5 μL of the PI solution was added to the tube, and the samples were analyzed in flow cytometry apparatus (BD FACSCalibur™, Biosciences, San Jose, CA, USA).

Reverse Transcription Polymerase Chain Reaction for Caspase-3

Small kidney sections were directly snap-frozen in liquid nitrogen. The extraction of the total RNA was carried out using QIAzol reagent according to the protocol recommended by the producer. Subsequent to standard protocols, reverse transcription polymerase chain reaction (RT-PCR) was accomplished. The cDNA was synthesized by reverse-transcribing the total RNA (2.5 μg) with Superscript II (50 μL), using the producer's instruction. The reaction was primed using 300 ng of random primers (Table 1). Ethanol-precipitated cDNA (100 ng) was selected as a template for the following PCR reaction. The primer sequences and cycling conditions for semi-quantitative PCR included 94°C for 3 minutes, annealing for 30 seconds, and extension at 72°C for 30 seconds.

Statistical Analysis

The data were represented as a mean \pm standard error (SE), and their analysis was conducted by one-way analysis of variance (ANOVA) with Tukey's post hoc test, using SPSS 20 software. The value of $P < 0.05$ was considered as statistically significant.

Results

HPLC Findings on Extract Ingredients

Flavonoids and phenolic components were determined by HPLC. In the leaf extract, we observed high levels of flavonoids (25.84%) and phenolic compounds (32.84%). However, the levels of alkaloids and scavenger property were low (34.7%), but IC_{50} effects were high (>200). The sum of the total alkaloids of the leaf extract was only 0.14% (Table 2).

Biochemical Effects of Peganum harmala Leaf Extract

The measurement of serum creatinine indicated a significant difference in the diabetic and control groups ($P < 0.05$). The results showed non-significant differences between the diabetic and D+L groups (Figure 1A).

Table 1. Primers Sequences

Name	Sequence (5'→ 3')
Caspase-3 (Forward)	AGCTTCTTCAGAGGCGACTA
Caspase-3 (Reverse)	GGACACAATACACGGGATCT (29)
GAPDH (Forward)	CTCAAGATTGTCAGCAATGC
GAPDH (Reverse)	CAGGATGCCCTTAGTGGGC (30)

Table 2. Active Ingredients of the Leaf Extract

Active Components of the Extract	Leaf
Extraction (%)	31.7
Alkaloids	
Harmine	0.055
Harmaline	0.05
Harmone	0.011
Harmol	0
Harmalol	0.026
Antioxidant	>200
IC ₅₀ Scavenger %	34.7
Whole phenolic quantity (mg GAE/mg extract) at 200 mg/mL	32.84
Total flavonoid quantity (mg QE/mg extract)	25.84

Moreover, no meaningful changes were detected in the creatinine of rats in the control groups. In serum urea diagram, STZ-diabetic rats significantly elevated the serum levels of urea compared to the control rats ($P < 0.001$). Our findings also revealed no significant differences between the diabetic and D+L groups, suggesting that there is no significant decrease in the serum levels of urea in the D+L group (Figure 1B).

After treatment, the serum albumin level in the diabetic group demonstrated a meaningful reduction compared to the control group ($P < 0.01$). Also, albumin remarkably reduced in the D+L group. There were no significant differences between the control and C+L groups (Figure 1C).

Histopathological Evaluation of *Peganum harmala* Leaf Extract

Glomeruli basement membrane disruption was visible in the H&E-stained kidney sections of diabetic groups. Vacuolation was also presented in the glomeruli and in the cortex. Interstitial Edema was confirmed, and some necrotic cells formed in the medulla (score 4). No principal histological differences were found in the tissue structure of the control group compared to C+L group (score 0; Figure 2).

In D+L mice group, some glomeruli were destroyed, and the epithelial tissue was lost (score 3). Microscopic studies were performed in epithelial diversity, tubular degeneration, leukocyte influx, and capillary mass. Comparing the epithelial diversity in the rats' kidney in control and diabetic groups indicated that diabetic tissue severely degraded. Capillary mass in diabetic rats was more than D+L ones. The healing effects of the leaf extract were not detected in the D+L group. Leukocyte influx and tubular degeneration were significantly higher in the diabetic than the control rats. Kidney tissue assessment displayed that the leaf extract could not reduce damages caused by diabetes in the kidney (Table 3).

Light microscopic exploration of AgNOR-stained

sections of the diabetic rats' kidney is shown in Figure 3. In the D+L group, no increased appearance of black nuclei was found inside the glomerulus, and medulla indicates no positive effect of the extract on the kidney tissue in the D+L group. In the kidney of the control groups, the animals were exposed to the same amount of transformation as the C+L group, and no negative effects were observed (Figure 3). Based on the Figure 4, the AgNOR staining of all the groups for counting the live cells reveals a significant decrease in the diabetic group in comparison to the control group ($P < 0.001$). However, a considerable growth was not seen in the D+L group when compared with the diabetic group. Accordingly, maximum values were detected in the control group.

Apoptotic Investigations of Kidney

Our overall goal was to quantify all apoptotic cells in the kidney tissue with the flow cytometry. Figure 5 illustrates

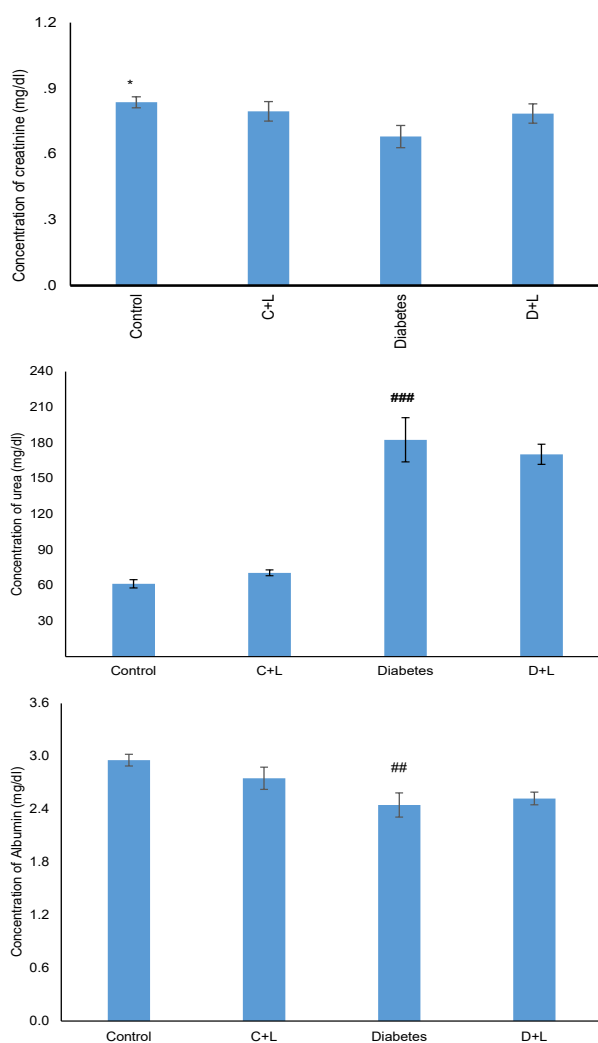


Figure 1. (A) Creatinine Plasma Level Between Diabetic and Experimental Groups.

(B) Urea Plasma Level Between Diabetic and Experimental Groups. (C) Albumin Plasma Level Between Diabetic and Control Groups. All values are represented by mean \pm SE. N=8. * $P < 0.05$ compared with diabetic; ## $P < 0.01$ compared with control.

Table 3. Kidney Tissue Evaluation of All Animals

Groups	Capillary Mass (%)	Leukocyte Influx (%)	Epithelial Diversity (%)	Tubular Degeneration (%)
Control	15±20	7±6	15±20	7±10
C+L	20±25	10±5	20±25	5±10
Diabetes	76±79 ^{###}	41±44 ^{###}	81±79 ^{###}	64±71 ^{###}
D+L	60±70	40±40	65±70 ^{***}	40±40 ^{***}

^{###}Significance, when compared to the control group. ^{***} Significance, when compared to the diabetic group; ($P < 0.05$).

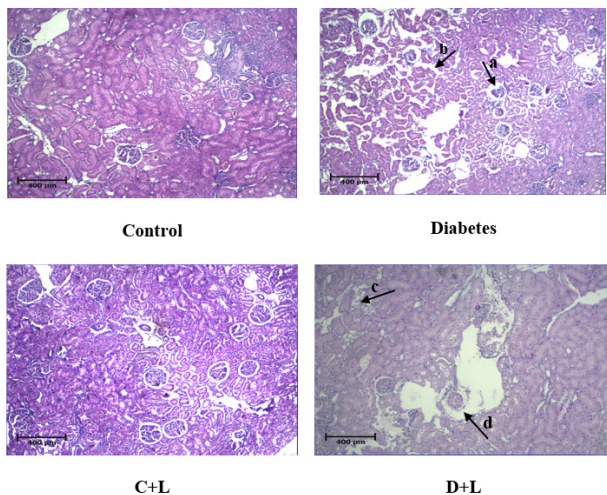


Figure 2. Photomicrographs of H&E Staining in All Groups (x40). a: glomerular damage, b: epithelial disruption, c: epithelial damaging, d: vessel dilation.

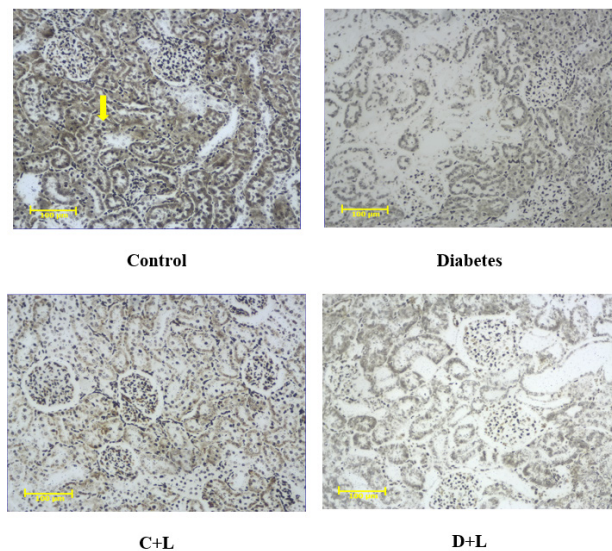


Figure 3. Histological Micrographs of AgNOR-stained Kidney Sections in All Groups (x100). The thick arrow shows AgNOR staining.

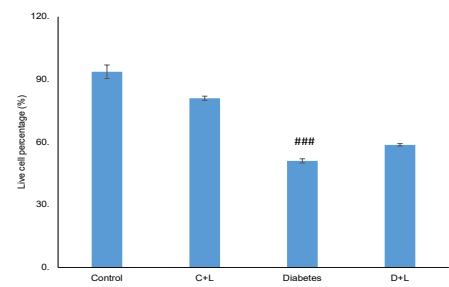


Figure 4. Live Cell Percentages in AgNOR Staining Between Diabetic and Control Groups. All values are represented by mean ± SE (n=8). ^{###} $P < 0.001$ compared with the control group.

the results of apoptotic analysis of kidney in all groups of rats. Total apoptosis results of the leaf extract were obtained from all initial and delayed quadrants (Figure 6). STZ administration significantly enhanced apoptosis levels in the diabetic group as compared to those of the control group ($P < 0.05$). The apoptosis in the C+L group was in the same level as the control group (Figure 6). In the caspase-3 diagram, the diabetic group showed a significant increase relative to the control group ($P < 0.001$). The D+L group indicated the same level of gene expression as the diabetic rats. There was also no meaningful difference between the control and C+L groups (Figure 7).

Discussion

There are various research studies showing the effects of alkaloids and flavonoids on apoptosis reduction (22,31,32). Diabetes is a growing disorder worldwide, and its treatment with herbal medicines may produce less side effects and low costs (33). The present study was designed to evaluate the leaf part of a wild plant called *P. harmala*, which contains varied amounts of alkaloids and flavonoids and other ingredients. We also assessed the main components of the leaf that act as an anti-apoptotic factor in the kidney.

In this survey, low levels of β -carboline alkaloids, especially harmaline and harmine, were detected in the leaf extract of *P. harmala* in addition to its low antioxidant activity, but the main positive point was the presence of high percentage of flavonoids. Additionally, the administration of *P. harmala* leaf extract could not lead to the anti-apoptotic effects in the kidney by decreasing caspase-3 and the tissue damage caused by diabetes remained in the kidney. Therefore, the *P. harmala* leaf extract was not able to ameliorate apoptosis.

Clinically, the levels of serum creatinine and urea boosted significantly in the group of diabetic rats with impaired kidney function; this result has been supported by a similar study (34). Creatinine measurement suggested no significant changes in the D+L group. In line with these findings, Kashi et al implied that in diabetic patients treated with *P. harmala*, the serum creatinine level did not reduce significantly compared to the diabetic control group (35). In another study, the use of the seed extract

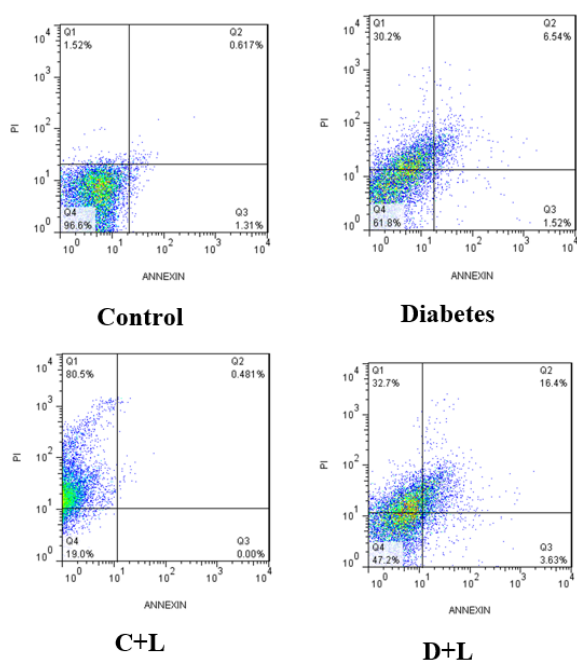


Figure 5. Flow Cytometry Analysis of Annexin V and PI Staining of Kidney Tissue. Necrotic and viable cells are shown in the upper and lower left quarters of the panel, FITC-Annexin V negative, and PI positive, respectively. Late and early apoptotic cells are indicated in the upper and lower right quarters, positive for FITC-Annexin V binding, and for PI uptake, respectively.

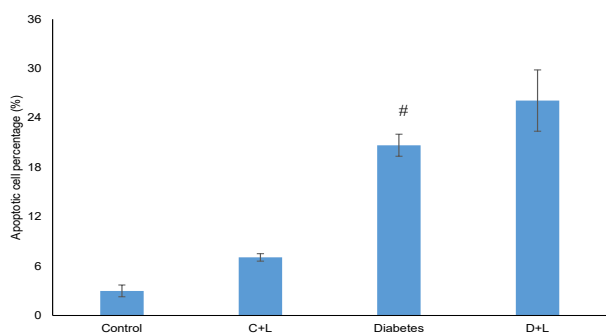


Figure 6. Apoptosis Rate Between Control and Diabetic Groups. All values are represented by mean \pm S.E. N=8. # $P < 0.05$ compared with control.

resulted in a relative decrease in the urea level and reached the level of urea in normal rabbits (36). In the present research, plasma albumin levels remarkably decreased in the diabetic group, but in the control group, the result was opposite. Pourali et al observed that in diabetic patients, serum albumin decreased due to increased glucose, insulin deficiency, and renal dysfunction (37). Based on our recent results, the lower percentages of alkaloids such as harmine presented in the methanolic extract of the leaf seems to be involved in such results (38).

STZ has been introduced as the inducer of caspase-3 mRNA expression in the kidney of the DN rats (39). Our observations reflected that the *apoptotic cell* death was significantly higher in the diabetic group than the

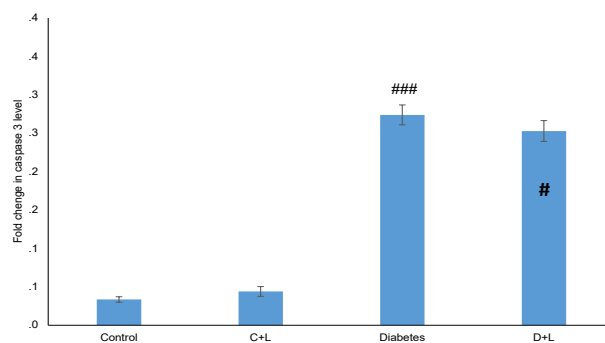


Figure 7. Caspase-3 Kidney Level Between Diabetic and Control Groups.

Data are presented as mean \pm SE. N=8. ### $P < 0.001$ compared with control.

control one. In accordance with the findings of our study, a research suggested that hyperglycemia plays a key role in the pathogenesis of nephropathy in uncontrolled diabetes mellitus and causes severe damage to the structure and function of the kidney (40). Given the existing data, the amount of apoptosis was not significantly higher in the rats of D+L group. Evidence has divulged that β -carboline alkaloids form the most important structures of *P. harmala*, and this plant and its alkaloids are featured with the anti-inflammatory activity (41). Our findings revealed that the *P. harmala* leaf extract contains a low percentage of β -carbolines and high percentage of flavonoids compounds, making it unable to show its anti-apoptotic effects on the kidney tissue. Considering the anti-apoptotic effects of the seed extract and the presence of harmine alkaloid in the seed extract, it can be postulated that harmine in the seed may prevent the NF- κ B apoptotic pathway (42). Consistent with these results, Niu et al disclosed that harmine is able to improve inflammation and oxidative stress brought by lipopolysaccharides through this pathway. It has also been demonstrated that the stimulation of the NF- κ B pathway can support apoptosis (43), and NF- κ B could persuade the expression of caspase-induced apoptosis (44). The anticancer activities of flavonoids, as we observed in the leaf extracts, have been proven in animal and human kidney models, by inhibiting cell proliferation and inducing apoptosis with varied amounts of IC_{50} (45-47).

Caspases, a family of cysteine proteases, are mostly associated with the apoptotic pathway (49). In the present study, the expression of caspase-3 in the diabetic group was significantly greater than that of the control, which is in conformity with this result that caspase-3 is expressed through apoptosis (49). The same amount of caspase-3 gene expression in the D+L group was correlated with an investigation indicating the considerable role of flavonoids in the apoptosis of the kidney (47). As reported earlier, flavonoids probably stimulate apoptosis through the development of caspases-3, -8, and -9 in the cellular pathway (50,51). In this regard, Bremner et al pointed out

that *P. harmala* alkaloids are linked with the inhibition of the inflammasome pathways, which verifies our results (41). Moreover, it has been exhibited that harmine, as the major alkaloid source of the seed extract, can mitigate the expression of the caspase-3 gene (38).

Histological examination of diabetic rats evinced a correlation between convoluted tubules, a raise in Bowman's capsule space due to the glomeruli reduction, and blood infiltration in the tubules. In rats of the control and C+L groups, glomeruli and Bowman's capsule and the urinary-collecting tubes were normal. Besides, some tissue damages remained unrepaired in the rats of D+L group, and reconstruction was not observed in parts such as Bowman's capsule, glomeruli, and urinary tract. In support of our observations, a study with the repeated administration of *P. harmala* alcoholic extract conducted on the kidney tissue displayed a mild degeneration in the epithelial cells of the proximal convoluted tubules (52). Also, histological and biochemical screening of *P. harmala* leave extracts indicated no apparent toxic effects on the kidney (53), but liver degeneration was observable in rats (34).

The mean AgNOR counts and area of distribution within the nucleus are beneficial for diagnosing the histological appearance of various diseases (54). In this study, the number of AgNOR dots reduced in the diabetic group. It is noteworthy that the higher apoptotic index is in correlation with the lower number of AgNOR dots in varied diseases (55). Similar to our results, Mohamed et al evidenced the eosinophil degeneration and small nuclei in diabetic rats (56). These findings support our results showing a significant decrease of nucleus dots in the diabetic rats. In line with our leaf extract findings, it has been observed that alkaloids have protective effects on kidney functions (31), and flavonoids could induce acute nephropathy (32). Based on the results presented in our previous research, the *P. harmala* seed extract can amend STZ-induced type 2 diabetes, a factor resulting in the increased apoptosis (38). Also, an earlier investigation suggested that in harmine-treated rats, the total of glomeruli increased and the thickness of the glomeruli decreased (14).

Our findings revealed that the administration of *P. harmala* leaf extract may preserve the apoptotic effects of diabetic kidney as the leaves of *P. harmala* contain a low level of alkaloids, such as harmine, and high flavonoid levels. However, these compounds did not show any toxic effect on the kidneys, possibly owing to the dose of the drug that could not inhibit the apoptotic pathway. Furthermore, the presence of some inactive forms of flavonoid compounds is possibly the reason why the extract could not prevent the mechanism of caspases action (35,38). Reports have suggested that the uptake of flavonoids and their metabolism in vivo depends on the cell type and their interaction with the cell membrane or their entrance to the cytosol. This matter is of great importance because

flavonoids have recently been introduced as the potential modulators of intracellular signaling cascades (57). However, further research is needed to develop the method of injection or effective treatment period for improving the apoptosis in the kidney cells.

Conclusion

The leaf extract of *P. harmala* was not able to reduce the apoptotic effects due to low amounts of alkaloids and high flavonoids components. Thus, flavonoids, as the most abundant ingredients in the *P. harmala* leaves, serve as the main player of apoptotic effects of the plant. Accordingly, the *P. harmala* leaf extract that contains high flavonoids and low alkaloids level has no anti-apoptotic and therapeutic effect on diabetes. On the other hand, the compounds of these substances together have no harmful effects on kidney tissue.

Authors' Contribution

FK, SO, RA, and AE contributed to the design and implementation of the research, to the analysis of the results, and to the writing of the manuscript.

Conflict of Interest Disclosures

The authors declare they have no conflict of interests.

Ethical issues

The protocol for care and use of animals was approved by the Ethics Committee of the Islamic Azad University, Science and Research Branch, Tehran, Iran (code: IR.IAU.SRB.REC.1396.38).

Acknowledgments

The authors would like to extend their sincere appreciation to the Islamic Azad University, Science and Research Branch, Tehran, Iran, for project support.

Funding

None.

References

1. Tabish SA. Is diabetes becoming the biggest epidemic of the twenty-first century? *Int J Health Sci (Qassim)*. 2007;1(2):V-VIII.
2. Qiao Y, Gao K, Wang Y, Wang X, Cui B. Resveratrol ameliorates diabetic nephropathy in rats through negative regulation of the p38 MAPK/TGF- β 1 pathway. *Exp Ther Med*. 2017;13(6):3223-30. doi: [10.3892/etm.2017.4420](https://doi.org/10.3892/etm.2017.4420).
3. Arroba AI, Frago LM, Argente J, Chowen JA. Activation of caspase 8 in the pituitaries of streptozotocin-induced diabetic rats: implication in increased apoptosis of lactotrophs. *Endocrinology*. 2005;146(10):4417-24. doi: [10.1210/en.2005-0517](https://doi.org/10.1210/en.2005-0517).
4. Bălăşescu E, Ion DA, Cioplea M, Zurac S. Caspases, cell death and diabetic nephropathy. *Rom J Intern Med*. 2015;53(4):296-303. doi: [10.1515/rjim-2015-0038](https://doi.org/10.1515/rjim-2015-0038).
5. Allen DA, Harwood S, Varagunam M, Raftery MJ, Yaqoob MM. High glucose-induced oxidative stress causes apoptosis in proximal tubular epithelial cells and is mediated by multiple caspases. *FASEB J*. 2003;17(8):908-10. doi: [10.1096/fj.02-](https://doi.org/10.1096/fj.02-)

- 0130fje.
- Habib SL. Diabetes and renal tubular cell apoptosis. *World J Diabetes*. 2013;4(2):27-30. doi: 10.4239/wjd.v4.i2.27.
 - Peter ME, Heufelder AE, Hengartner MO. Advances in apoptosis research. *Proc Natl Acad Sci U S A*. 1997;94(24):12736-7. doi: 10.1073/pnas.94.24.12736.
 - Fathiazad F, Azarmi Y, Khodaie L. Pharmacological effects of *Peganum harmala* seeds extract on isolated rat uterus. *Iranian Journal of Pharmaceutical Sciences*. 2006;2(2):81-6.
 - Moura DJ, Richter MF, Boeira JM, Pêgas Henriques JA, Saffi J. Antioxidant properties of beta-carboline alkaloids are related to their antimutagenic and antigenotoxic activities. *Mutagenesis*. 2007;22(4):293-302. doi: 10.1093/mutage/gem016.
 - Monsef HR, Ghobadi A, Iranshahi M, Abdollahi M. Antinociceptive effects of *Peganum harmala* L. alkaloid extract on mouse formalin test. *J Pharm Pharm Sci*. 2004;7(1):65-9.
 - Hasani-Ranjbar S, Larijani B, Abdollahi M. A systematic review of Iranian medicinal plants used in diabetes mellitus. *Arch Med Sci*. 2008;4(3):285-92.
 - Li S, Yang B, Zhang Q, Zhang J, Wang J, Wu W. Synthesis and bioactivity of beta-carboline derivatives. *Nat Prod Commun*. 2010;5(10):1591-6.
 - Rudolph A, Sainz J, Hein R, Hoffmeister M, Frank B, Försti A, et al. Modification of menopausal hormone therapy-associated colorectal cancer risk by polymorphisms in sex steroid signaling, metabolism and transport related genes. *Endocr Relat Cancer*. 2011;18(3):371-84. doi: 10.1530/erc-11-0057.
 - Salahshoor MR, Gholami Mahmoudian Z, Roshankhah S, Farokhi M, Jalili C. Harmine shows therapeutic activity on nicotine-induced liver failure in mice. *Histol Histopathol*. 2019;34(10):1185-93. doi: 10.14670/hh-18-122.
 - Komeili G, Hashemi M, Bameri-Niafar M. Evaluation of antidiabetic and antihyperlipidemic effects of *Peganum harmala* seeds in diabetic rats. *Cholesterol*. 2016;2016:7389864. doi: 10.1155/2016/7389864.
 - Zhao Y, Huang W, Wang J, Chen Y, Huang W, Zhu Y. Taxifolin attenuates diabetic nephropathy in streptozotocin-induced diabetic rats. *Am J Transl Res*. 2018;10(4):1205-10.
 - Kumar D, Zimpelmann J, Robertson S, Burns KD. Tubular and interstitial cell apoptosis in the streptozotocin-diabetic rat kidney. *Nephron Exp Nephrol*. 2004;96(3):e77-88. doi: 10.1159/000076749.
 - Motawi TK, Ahmed SA, M AH, El-Maraghy SA, W MA. Melatonin and/or rowatinex attenuate streptozotocin-induced diabetic renal injury in rats. *J Biomed Res*. 2019;33(2):113-21. doi: 10.7555/jbr.31.20160028.
 - Asgharpour M, Tolouian A, Bhaskar LV, Tolouian R, Massoudi N. Herbal antioxidants and renal ischemic-reperfusion injury; an updated review. *J Nephropharmacol*. 2021;10(1):e03. doi: 10.34172/npj.2021.03.
 - Malik S, Suchal K, Khan SI, Bhatia J, Kishore K, Dinda AK, et al. Apigenin ameliorates streptozotocin-induced diabetic nephropathy in rats via MAPK-NF- κ B-TNF- α and TGF- β 1-MAPK-fibronectin pathways. *Am J Physiol Renal Physiol*. 2017;313(2):F414-F22. doi: 10.1152/ajprenal.00393.2016.
 - Yang K, Li WF, Yu JF, Yi C, Huang WF. Diosmetin protects against ischemia/reperfusion-induced acute kidney injury in mice. *J Surg Res*. 2017;214:69-78. doi: 10.1016/j.jss.2017.02.067.
 - Zheng H, Lan J, Li J, Lv L. Therapeutic effect of berberine on renal ischemia-reperfusion injury in rats and its effect on Bax and Bcl-2. *Exp Ther Med*. 2018;16(3):2008-12. doi: 10.3892/etm.2018.6408.
 - Jin ZH, Gao P, Liu ZT, Jin B, Song GY, Xiang TY. Composition of ophiopogon polysaccharide, notoginseng total saponins and rhizoma *Coptidis* alkaloids inhibits the myocardial apoptosis on diabetic atherosclerosis rabbit. *Chin J Integr Med*. 2020;26(5):353-60. doi: 10.1007/s11655-018-3014-2.
 - Shao H, Huang X, Zhang Y, Zhang C. Main alkaloids of *Peganum harmala* L. and their different effects on dicot and monocot crops. *Molecules*. 2013;18(3):2623-34. doi: 10.3390/molecules18032623.
 - Hayet E, Maha M, Mata M, Gannoun S, Laurent G, Aouni M. Biological activities of *Peganum harmala* leaves. *Afr J Biotechnol*. 2010;9(48):8199-205. doi: 10.5897/ajb10.564.
 - Akbary P, Fereidouni MS, Akhlaghi M. In vitro antibacterial activity of *Peganum harmala* (L) extract to some fish pathogenic bacteria. *Iranian Journal of Aquatic Animal Health*. 2015;1(1):7-16. [Persian].
 - Derakhshanfar A, Oloumi MM, Mirzaie M. Study on the effect of *Peganum harmala* extract on experimental skin wound healing in rat: pathological and biomechanical findings. *Comp Clin Path*. 2009;19(2):169-72. doi: 10.1007/s00580-009-0848-1.
 - Elansary HO, Szopa A, Kubica P, Ekiert H, Al-Mana FA, El-Shafei AA. Polyphenols of *Frangula alnus* and *Peganum harmala* leaves and associated biological activities. *Plants (Basel)*. 2020;9(9). doi: 10.3390/plants9091086.
 - Cai Y, Li J, Yang S, Li P, Zhang X, Liu H. CIBZ, a novel BTB domain-containing protein, is involved in mouse spinal cord injury via mitochondrial pathway independent of p53 gene. *PLoS One*. 2012;7(3):e33156. doi: 10.1371/journal.pone.0033156.
 - Wang YF, Wu M, Ma BJ, Cai DA, Yin BB. Role of high mobility group box-1 and protection of growth hormone and somatostatin in severe acute pancreatitis. *Braz J Med Biol Res*. 2014;47(12):1075-84. doi: 10.1590/1414-431x20143165.
 - Wang Y, Fu X, Wang X, Jia X, Gu X, Zhang J, et al. Protective effects of anisodamine on renal function in patients with ST-segment elevation myocardial infarction undergoing primary percutaneous coronary intervention. *Tohoku J Exp Med*. 2011;224(2):91-7. doi: 10.1620/tjem.224.91.
 - Lin JL, Ho YS. Flavonoid-induced acute nephropathy. *Am J Kidney Dis*. 1994;23(3):433-40. doi: 10.1016/s0272-6386(12)81008-0.
 - Modak M, Dixit P, Londhe J, Ghaskadbi S, Devasagayam TP. Indian herbs and herbal drugs used for the treatment of diabetes. *J Clin Biochem Nutr*. 2007;40(3):163-73. doi: 10.3164/jcbn.40.163.
 - Lamchouri F, Settaf A, Cherrah Y, El Hamidi M, Tligui N, Lyoussi B, et al. Experimental toxicity of *Peganum harmala* seeds. *Ann Pharm Fr*. 2002;60(2):123-9.
 - Kashi Z, KRabiei K, Mosavidarka SS, Bahar A, Akha O, Karami M. The combination effect of five herbal drugs" *Peganum harmala*, *Quercus infectoria*, *Vaccinium myrtillus*, *Citrullus colocynthis*, *Securigera securidaca*" on blood glucose. *Iranian Journal of Diabetes & Obesity (IJDO)*. 2014;6(2):67-73.
 - Noor Alzamili S. Effect of *Peganum harmala* seeds alcoholic extract on kidney efficiency, thyroid stimulating hormone and thyroid gland hormones in local female rabbits. *Al-Qadisiyah Journal of Veterinary Medicine Sciences*. 2016;15(2):20-4. doi: 10.29079/vol15iss2art391.
 - Pourali P, Hojati V, Roudi B. The effect of berberine on blood albumin and the liver enzymes in the healthy and streptozotocin-induced diabetic rats. *Journal of Neyshabur University of Medical Sciences*. 2018;5(4):1-8. [Persian].
 - Kajbaf F, Oryan S, Ahmadi R, Eidi A. Harmine, a natural β -carboline alkaloid, ameliorates apoptosis by decreasing the expression of caspase-3 in the kidney of diabetic male Wistar rats. *Gene Rep*. 2020;21:100863. doi: 10.1016/j.genrep.2020.100863.
 - Yuan H, Zhang X, Zheng W, Zhou H, Zhang BY, Zhao D. Minocycline attenuates kidney injury in a rat model of streptozotocin-induced diabetic nephropathy. *Biol Pharm Bull*. 2016;39(8):1231-7. doi: 10.1248/bpb.15-00594.
 - Zhang X, Barile G, Chang S, Hays A, Pachydaki S, Schiff W, et al. Apoptosis and cell proliferation in proliferative retinal disorders:

- PCNA, Ki-67, caspase-3, and PARP expression. *Curr Eye Res.* 2005;30(5):395-403. doi: [10.1080/02713680590956306](https://doi.org/10.1080/02713680590956306).
41. Bremner P, Rivera D, Calzado MA, Obón C, Inocencio C, Beckwith C, et al. Assessing medicinal plants from South-Eastern Spain for potential anti-inflammatory effects targeting nuclear factor-Kappa B and other pro-inflammatory mediators. *J Ethnopharmacol.* 2009;124(2):295-305. doi: [10.1016/j.jep.2009.04.035](https://doi.org/10.1016/j.jep.2009.04.035).
 42. Niu X, Yao Q, Li W, Zang L, Li W, Zhao J, et al. Harmine mitigates LPS-induced acute kidney injury through inhibition of the TLR4-NF-κB/NLRP3 inflammasome signalling pathway in mice. *Eur J Pharmacol.* 2019;849:160-9. doi: [10.1016/j.ejphar.2019.01.062](https://doi.org/10.1016/j.ejphar.2019.01.062).
 43. Khandelwal N, Simpson J, Taylor G, Rafique S, Whitehouse A, Hiscox J, et al. Nucleolar NF-κB/RelA mediates apoptosis by causing cytoplasmic relocalization of nucleophosmin. *Cell Death Differ.* 2011;18(12):1889-903. doi: [10.1038/cdd.2011.79](https://doi.org/10.1038/cdd.2011.79).
 44. Yang HJ, Wang M, Wang L, Cheng BF, Lin XY, Feng ZW. NF-κB regulates caspase-4 expression and sensitizes neuroblastoma cells to Fas-induced apoptosis. *PLoS One.* 2015;10(2):e0117953. doi: [10.1371/journal.pone.0117953](https://doi.org/10.1371/journal.pone.0117953).
 45. Zhang HW, Hu JJ, Fu RQ, Liu X, Zhang YH, Li J, et al. Flavonoids inhibit cell proliferation and induce apoptosis and autophagy through downregulation of PI3Kγ mediated PI3K/AKT/mTOR/p70S6K/ULK signaling pathway in human breast cancer cells. *Sci Rep.* 2018;8(1):11255. doi: [10.1038/s41598-018-29308-7](https://doi.org/10.1038/s41598-018-29308-7).
 46. Hashemzaei M, Delarami Far A, Yari A, Heravi RE, Tabrizian K, Taghdisi SM, et al. Anticancer and apoptosis-inducing effects of quercetin in vitro and in vivo. *Oncol Rep.* 2017;38(2):819-28. doi: [10.3892/or.2017.5766](https://doi.org/10.3892/or.2017.5766).
 47. Polukonova NV, Navolokin NA, Bucharskaya AB, Mudrak DA, Baryshnikova MA, Stepanova EV, et al. The apoptotic activity of flavonoid-containing *Gratiola officinalis* extract in cell cultures of human kidney cancer. *Russ Open Med J.* 2018;7(4):1-6.
 48. Thornberry NA, Lazebnik Y. Caspases: enemies within. *Science.* 1998;281(5381):1312-6. doi: [10.1126/science.281.5381.1312](https://doi.org/10.1126/science.281.5381.1312).
 49. Erboga M, Aktas C, Erboga ZF, Donmez YB, Gurel A. Quercetin ameliorates methotrexate-induced renal damage, apoptosis and oxidative stress in rats. *Ren Fail.* 2015;37(9):1492-7. doi: [10.3109/0886022x.2015.1074521](https://doi.org/10.3109/0886022x.2015.1074521).
 50. Das A, Banik NL, Ray SK. Flavonoids activated caspases for apoptosis in human glioblastoma T98G and U87MG cells but not in human normal astrocytes. *Cancer.* 2010;116(1):164-76. doi: [10.1002/cncr.24699](https://doi.org/10.1002/cncr.24699).
 51. Choi EJ, Kim GH. Apigenin induces apoptosis through a mitochondria/caspase-pathway in human breast cancer MDA-MB-453 cells. *J Clin Biochem Nutr.* 2009;44(3):260-5. doi: [10.3164/jcbn.08-230](https://doi.org/10.3164/jcbn.08-230).
 52. Mohamed AHS, Al-Jammali SMJ, Naki ZJ. Effect of repeated administration of *Peganum harmala* alcoholic extract on the liver and kidney in Albino mice: a histo-pathological study. *J Sci Innov Res.* 2013;2(3):585-97.
 53. Muhi-eldeen Z, Al-Shamma KJ, Al-Hussainy TM, Al-Kaissi EN, Al-Daraji AM, Ibrahim H. Acute toxicological studies on the extract of Iraqi *Peganum harmala* in rats. *Eur J Sci Res.* 2008;22(4):494-500.
 54. Raghunathan D, Kurady LB, Bhat R. Effect of methotrexate on AgNOR count in liver of Wistar rats. *Iranian Journal of Pharmacology and Therapeutics (IJPT).* 2009;8(1):11-5. [Persian].
 55. Ribeiro CV, Vasconcelos AC, de Souza Andrade-Filho J. Apoptosis and expression of argyrophilic nucleolus organizer regions in epithelial neoplasms of the larynx. *Braz J Otorhinolaryngol.* 2015;81(2):158-66. doi: [10.1016/j.bjorl.2014.12.003](https://doi.org/10.1016/j.bjorl.2014.12.003).
 56. Mohamed HE, El-Sweify SE, Hasan RA, Hasan AA. Neuroprotective effect of resveratrol in diabetic cerebral ischemic-reperfused rats through regulation of inflammatory and apoptotic events. *Diabetol Metab Syndr.* 2014;6(1):88. doi: [10.1186/1758-5996-6-88](https://doi.org/10.1186/1758-5996-6-88).
 57. Spencer JP, Abd-el-Mohsen MM, Rice-Evans C. Cellular uptake and metabolism of flavonoids and their metabolites: implications for their bioactivity. *Arch Biochem Biophys.* 2004;423(1):148-61. doi: [10.1016/j.abb.2003.11.010](https://doi.org/10.1016/j.abb.2003.11.010).